

Aggressive Peripheral Gangrene in a Young Man

Howaida E. Mansour, Ayah T. Moussa

Department of Internal Medicine – Rheumatology Division, Ain Shams University; Egypt

A 20-year-old male patient, porter, born and lives in Assiut, single, he smokes 40 cigarettes/day for 5 years, presented with blackish discoloration of fingers and toes of 15 days duration.

The condition started one year ago when the patient noticed a right inguinal painless swelling which he ignored.

Six months later, he developed right LL diffuse swelling with redness and pain; it was diagnosed as DVT for which he received anticoagulation therapy.

One and half month ago, he developed grade III dyspnea associated with stitching chest pain, generalized lymphadenopathy, continuous high-grade fever more at night and weight loss, Lymph node biopsy was done.

A week later, He was found to have pericardial effusion for which pericardiocentesis by pigtail catheter was done. Meanwhile, he developed bluish discoloration of fingers and toes that was progressed rapidly to blackish discoloration and extended to involve all fingers and toes. It was associated with edema and burning pain of hands and feet and bilateral ankle arthritis. He has recurrent oral and nasal ulcers but he denies any photosensitive rash, alopecia or Raynaud's phenomena. No symptoms suggestive of nephritis, dysphagia or muscle weakness. No bleeding tendency or infections. No history suggestive of other systems affection.

On Examination:

He is fully conscious, oriented with average body mass index, mood and intelligence. He is pale but no jaundice or cyanosis. BP 110/70, pulse 84 regular, equal, temp 37.2. There are ulcers on the upper lip, left angle of the mouth and oral cavity figure (1). He has generalized lymphadenopathy and hepatosplenomegaly. Distant heart sounds but normal breathing sound. There was bilateral extensive dry gangrene of almost all fingers; figure (2) and toes figures (3).

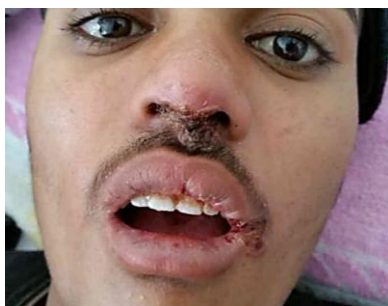

Figure (1)

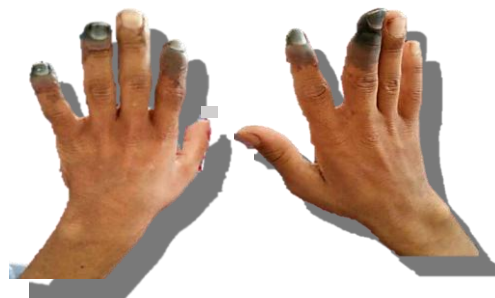


Figure (2)

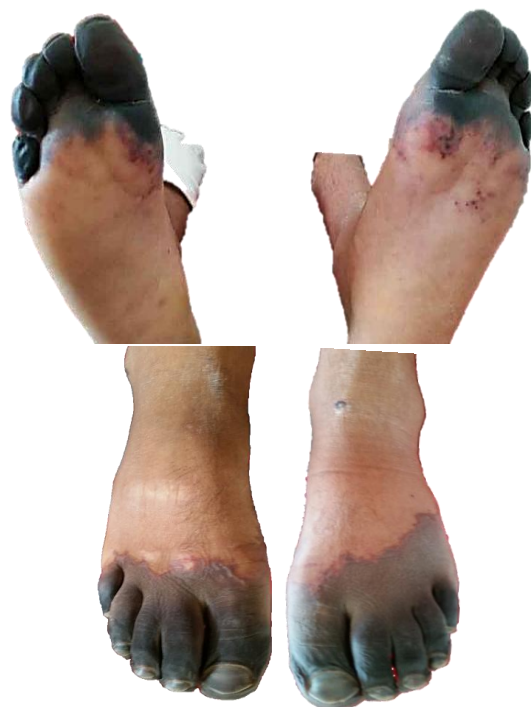

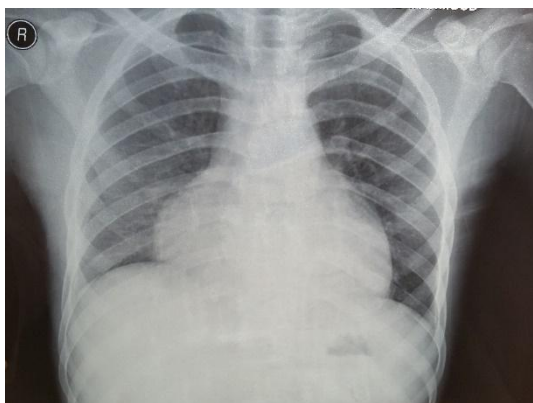
Figure (3)

Laboratory workup:

CBC: Hb 8.5 g/dl (mild normocytic normochromic anemia), WBC 9.6 cell/mm³, platelets 214 x 10³. Retics 5.1%, Coomb's test: negative, ESR: 120 mm, CRP 6 mg%. Blood chemistry; AST: 33 IU/L, ALT: 283 IU/L, Total proteins: 7.6 g/dl, Albumin: 2.6 g/dl

(low), LDH: 690 IU/L, s.creatinine 0.5 mg/dl, Fasting blood sugar 98 mg/dl, Total bilirubin 0.9 mg/dl
Urine analysis: albumin +ve, protein/creatinine (P/C) ratio: 0.4

ANA was positive with homogenous and rim pattern, DNA positive, HCV Ab: Positive, C-ANCA negative, P-ANCA: Positive. Anticardiolipin antibodies (ACL) and lupus anticoagulant (LA) are negative. Plain X-ray chest, Figure (4) showed inverted flask shape of massive pericardial effusion. Echocardiography: confirmed the presence of pericardial effusion. Abdominal ultrasound: showed hepatosplenomegaly with mild ascites. Lymph node biopsy: revealed reactive hyperplasia of lymph node, follicular pattern with progressively transformed germinal centers. Tuberculin test is negative. Arterio-venous duplex of Both UL & LL is normal. Bone marrow aspirate and trephine are normal.



Inverted flask shaped heart.

DISCUSSION

The acute onset of peripheral gangrene with normal arterial duplex in this young male patient points to systemic vasculitic process involving the small arterioles and capillaries. However, this vasculitis is not likely one of the known primary small vessels vasculitides, as there is no eosinophilia nor granuloma. In spite of the fact that HCV is a well known to cause cryoglobulinaemic vasculitis, an ANCA –ve small vessels vasculitis that may explain the extensive digital gangrene, yet it failed to explain the other associated clinical data (oral/ nasal ulcers, pericardial effusion, DVT and generalized lymphadenopathy). That is to say that neither primary vasculitis nor HCV associated vasculitis can explain the patient story.

Smoking with peripheral gangrene in a young male patient is a well known association in thromboangitis obliterans or Burger's disease, however again this disease would not explain the other

clinical data and the markedly elevated acute phase reactants (ESR/CRP).

The clinical and laboratory criteria of this young man all point to the diagnosis of systemic lupus erythematosus (SLE) associated with secondary vasculitis. He is fulfilling the SLICC classification criteria of SLE¹: Pericardial effusion, recurrent oral/nasal ulcers, evidence of nephritis, positive ANA with the specific rim and homogenous pattern and positive DNA testing. Regarding the ANA testing by indirect immunofluorescence technique is the best reliable laboratory method; The rim (peripheral) pattern is the most specific pattern for lupus², while the homogeneous (diffuse) pattern is the most common pattern in SLE.³ Digital ulcers and gangrene are common skin manifestations of active systemic connective tissue diseases although they are relatively rare in systemic lupus erythematosus.⁴ Additionally, It is rather common in SLE patients to present with generalized lymphadenopathy, hepatosplenomegaly fever and many was transferred to fever hospital as fever of unknown origin. In this challenging situation, it is very important to exclude hematological malignancies (Leukemias/ lymphomas), that is why lymph node biopsy and bone marrow examination were essential. This may be very confusing when lymphoma is associated with false positive ANA /DNA testing. So, in this young man there was a slowly progressive disease process that has been started many years ago but only recently he sought medical advice when it was complicated by pericardial effusion and aggressive digital gangrene.

Acknowledgment

Many thanks to the patient for accepting to report his medical data.

REFERENCES

1. Petri M, Orbai AM, Alarcón GS, et al. Derivation and validation of the Systemic Lupus International Collaborating Clinics classification criteria for systemic lupus erythematosus. *Arthritis Rheum.* Aug 2012; 64(8): 2677-86.
2. Murato P, Granito A, Ferri S, et al. Multiple nuclear dots and rim-like/membranous IgG isotypes in primary biliary cirrhosis. *Informa* 2009; 42(3): 224-227
3. Frodlund M, Dahlström Ö, Kastbom A, Skogh T, Sjöwall C. Associations between antinuclear antibody staining patterns and clinical features of systemic lupus erythematosus: analysis of a regional Swedish register. *BMJ Open* 2013;3(10)
4. Rosato E, Molinaro I, Pisarri S, et al. Digital Ulcers as an Initial Manifestation of Systemic Lupus Erythematosus. *Internal Medicine* (2011) 50(7): 767-769.

